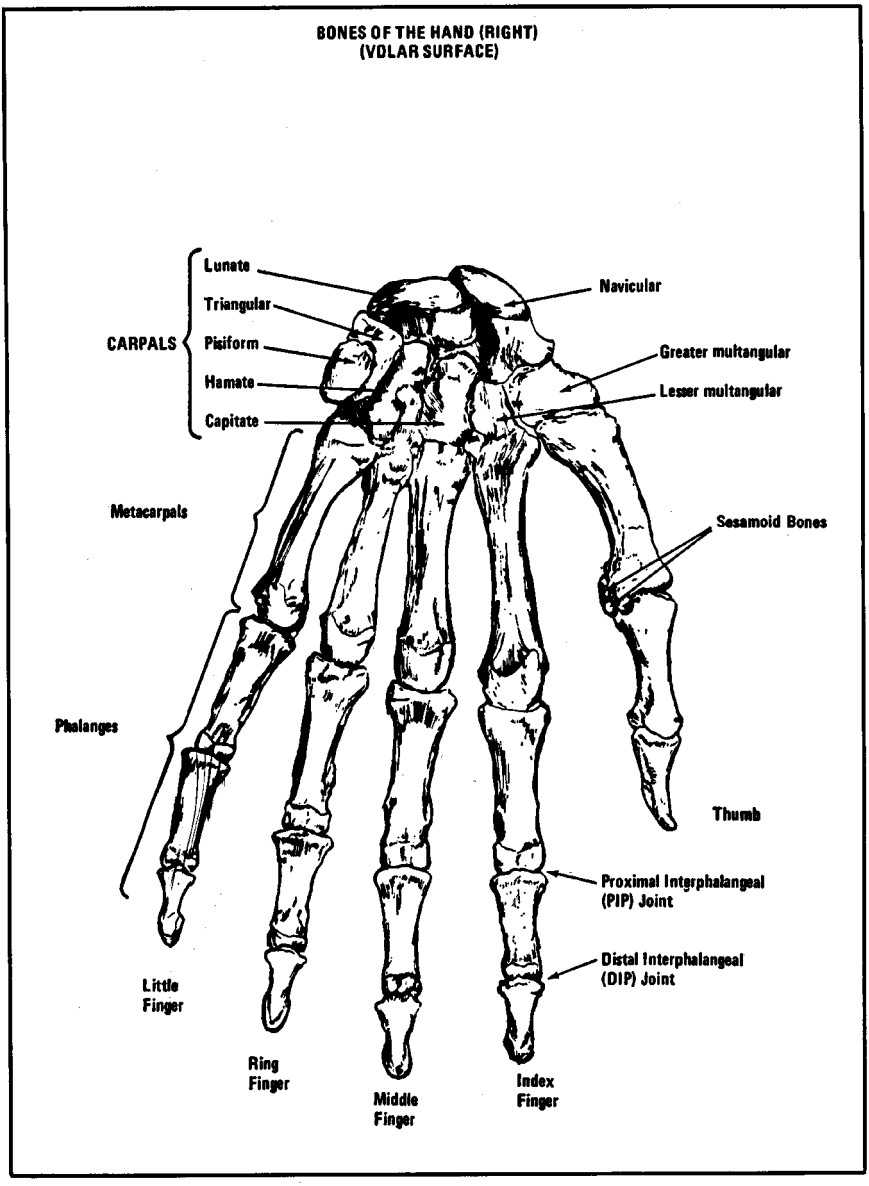
BONES OF THE HAND (RIGHT)
(VOLAR SURFACE)
CARPALS
Lunate
Triangular
Pisiform
Hamate
Capitate
Navicular
Greater multangular
Lesser multangular
Metacarpals
Sesamoid Bones
Phalanges
Thumb
Proximal Interphalangeal (PIP) Joint
Distal Interphalangeal (DIP) Joint
Little Finger
Ring Finger
Middle Finger
Index Finger

PLATE III